



**DATE PRESENTING CLINICAL SIGNS**

10/6/22

History: Pre-anesthetic evaluation (dental). Recently diagnosed with hyperthyroidism and receiving methimazole. One or more pulmonary nodules visualized in radiographs.

**ECHOCARDIOGRAPHIC FINDINGS**

**PERFORMED BY:**

Kelly Vazquez

2D, M-mode, and Doppler study.

Left atrial size is normal. The mitral valve is normal. Left ventricular wall thickness is normal. Left ventricular internal dimensions are normal. Left ventricular systolic function is hyperdynamic. The aorta and aortic valve are normal. Right atrial and right ventricular dimensions are normal. The tricuspid valve appears normal, though very mild tricuspid regurgitation is present. The pulmonary artery and pulmonic valve are normal. No shunting lesions are visualized. No pericardial effusion or cardiac masses are seen.

**INTERPRETED BY**

Keith Blass, DVM,  
MS, DACVIM  
(Cardiology)

**PATIENT**

Pumpkin Wilkerson-  
Galvin

LA/Ao - 1.32  
IVSd - 5.0 mm  
LVPWd - 5.0 mm  
LVIDd - 13.1 mm  
LVIDs - 5.3 mm  
FS - 59.5%  
LVOT - 1.11 m/s  
RVOT - 0.80 m/s

**SPECIES**

Feline

**ASSESSMENT/RECOMMENDATIONS**

The only abnormality seen in this exam is very mild regurgitation of blood across Pumpkin's tricuspid valve. The hemodynamic effects of the regurgitation are negligible, and Pumpkin's cardiac function appears to be well-compensated.

**BREED**

DSH

Pumpkin's cardiovascular risk for general anesthesia is low based on this exam, and there are no contraindications to the use of any specific anesthetic agents.

**SEX**

FS

No therapy is recommended based on this exam.

A recheck echocardiogram is recommended in 1 year, sooner if new clinical signs compatible with cardiac dysfunction develop.

**AGE**

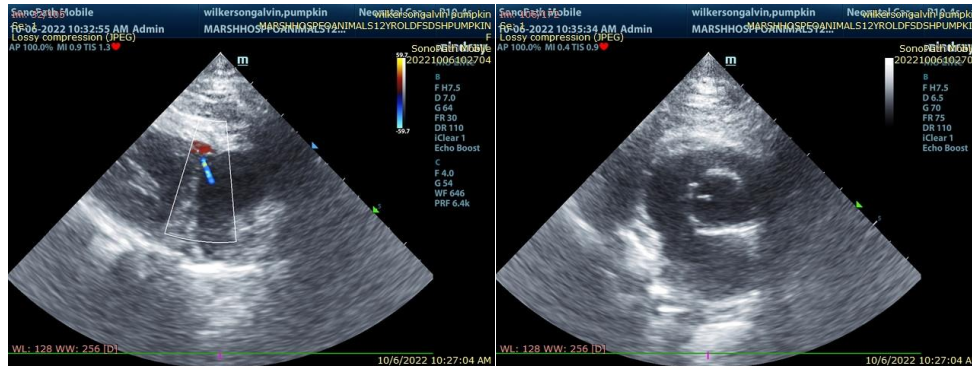
12 y

**WEIGHT**

17 lb

**HOSPITAL NAME**

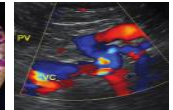
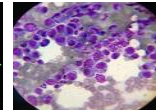
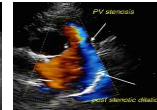
Marsh Hospital for  
Animals



**REFERRING VET**

Dr. Milwicki

The information and recommendations provided are based on the images presented by the



**DATE** referring veterinarian. No evaluation can be communicated regarding pathology that was not visible in the image/video clips provided.

10/6/22

Thank you for this referral. If the clinical or image interpretation does not parallel your findings or if I can be of any further assistance please contact me.

**PERFORMED BY:**

Kelly Vazquez

**Keith Blass, DVM, MS, DACVIM (Cardiology)**

KeithBlass@gmail.com

631-804-5754

**INTERPRETED BY**

Keith Blass, DVM,  
MS, DACVIM  
(Cardiology)

**PATIENT**

Pumpkin Wilkerson-  
Galvin

**SPECIES**

Feline

**BREED**

DSH

**SEX**

FS

**AGE**

12 y

**WEIGHT**

17 lb

**HOSPITAL NAME**

Marsh Hospital for  
Animals

**REFERRING VET**

Dr. Milwicki